


Candida utilis candidaemia in premature infants: a retrospective single-centre study

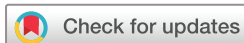Qiuping Li,^{1,2,3,4} Lu Zhuang,^{1,2,3,4} Sheng Zhang,^{1,2,3,4} Zhichun Feng ^{1,2,3,4}

To cite: Li Q, Zhuang L, Zhang S, et al. *Candida utilis* candidaemia in premature infants: a retrospective single-centre study. *BMJ Paediatrics Open* 2023;7:e002245. doi:10.1136/bmjpo-2023-002245

► Additional supplemental material is published online only. To view, please visit the journal online (<http://dx.doi.org/10.1136/bmjpo-2023-002245>).

QL and LZ contributed equally.

Received 22 August 2023
Accepted 24 October 2023



© Author(s) (or their employer(s)) 2023. Re-use permitted under CC BY-NC. No commercial re-use. See rights and permissions. Published by BMJ.

¹The Seventh Medical Centre of Chinese PLA General Hospital, Beijing, China

²Faculty of Pediatrics, the Chinese PLA General Hospital, Beijing, China

³National Engineering Laboratory for Birth Defects Prevention and Control of Key Technology, Beijing, People's Republic of China

⁴Beijing Key Laboratory of Pediatric Organ Failure, Beijing, People's Republic of China

Correspondence to
Professor Zhichun Feng;
zhichunfeng81@163.com

ABSTRACT

This retrospective study was conducted in a neonatal intensive care unit in Beijing. Patients whose blood culture yielded *Candida utilis* during hospitalisation from January 2009 to December 2017 were enrolled. Thirteen preterm infants of median gestational age 29.85 weeks were included. Laboratory tests on the day of onset showed thrombocytopenia in 11 patients, granulocytopenia in eight and elevated C-reactive protein in seven. No fungal endophthalmitis, renal infection, carditis or involvement of other end organs was observed in any of the cases. All 13 patients were cured after fluconazole therapy.

Preterm neonates in neonatal intensive care units (NICUs) are at high risk of undergoing various invasive procedures together with immature immunity. They are more likely to develop nosocomial infections, including fungal septicaemia.^{1 2} *Candida* species have become the third most common pathogens for late-onset septicaemia in newborn infants and are associated with a mortality rate of 20–34%.³ However, *Candida utilis* is seldom reported as the cause of candidaemia in humans.⁴ As a result, there is a lack of reliable information about its clinical features, treatment and prognosis. In the present study we performed a retrospective review of premature infants with *C. utilis* candidaemia (CUC) occurring in our NICU.

The retrospective study was conducted in the NICU of a public hospital in Beijing. Patients with CUC (see online Appendix) during hospitalisation were enrolled. Data including demographic characteristics, medical history, invasive procedures, medications, laboratory data and outcomes were collected.

From January 2009 to December 2017, CUC occurred in 13 premature infants (0.16%) out of a total of 79 863 neonates admitted to the NICU. The mean±SD birth gestational age of the 13 preterm infants with CUC was 29.85±1.14 weeks and the mean±SD birth weight was 1329.23±409.05 g (table 1).

The clinical manifestations are shown in table 2, the most frequent signs being poor response (9/13) and SaO₂ instability (11/13). In the 13 CUC cases (online supplemental table S1), thrombocytopenia was detected in 11 cases, granulocytopenia in eight cases and elevated C-reactive protein levels in seven cases on the day of onset. Cultures of cerebrospinal fluid were all negative. There was no sign of bone and joint infection, fungal endophthalmitis, renal infection, carditis or involvement of other end organs. All of the isolated strains were sensitive to amphotericin B, fluconazole, F-5 fluorine cytosine, voriconazole and itraconazole.

A peripherally inserted central catheter was removed after onset of the disease. Fluconazole was administered intravenously at a therapeutic dose of 8–10 mg/kg/day until the clinical symptoms of infection disappeared and two consecutive negative blood cultures were obtained at an interval of 1 week. The mean duration of anti-infective therapy was 24 days (range 18–31), including four cases receiving normal saline or plasma volume expansion therapy and three cases receiving vasoactive drugs. All the patients recovered from CUC after fluconazole treatment.

There have been rare reports about human CUC pathologies. A few available reports of CUC infection were in old people (68–88 years) and children (0–5 years), and treatments with flucytosine, fluconazole, liposomal amphotericin B or caspofungin improved the patients' condition.⁵

Candida spp, especially *C. albicans*, are more likely to be complicated by involvement of the end organs such as the brain, heart, kidney, eye and skeleton (online supplemental table S2)⁶ while, in the CUC cases in our study, no fungal endophthalmitis, renal infection, carditis, bone and joint infection or involvement of other end organs was observed. A G test was performed in seven patients and the level was elevated in only three cases,

Table 1 Perinatal history and general information of the infants

Characteristics or risk factors	Mean (SD) or n
General characteristics	
Mother	
Mother age, years	33.85 (4.06)
Mode of delivery	
Caesarean delivery	3
Vaginal delivery	10
Antenatal glucocorticoids (Yes)	7
PROM	1
GDM	1
GH	5
Colpitis	1
Infant	
Gestational age, weeks	29.85 (1.14)
Birth weight, g	1329.23 (409.05)
Sex (male)	6
Twins (Yes)	4
Apgar score (1 min)	8.08 (2.40)
Apgar score (5 min)	8.85 (1.41)
Prophylactic vaccination	0 (0.00)
Major diagnosis at admission	
RDS	11
PDA	9
Asphyxia	3
Metabolic acidosis	9
NEC	1
IVH	4
Hyperbilirubinaemia	2
Pneumonia	2
Duration of parenteral nutrition, days	38.15 (16.50)
PICC	6
Postnatal corticosteroid exposure	4
Tracheal intubation	9
Prophylaxis of fluconazole	4
Antibiotic exposure in 3 days before infection	
Piperacillin	2
Imipenem	7
Meropenem	1
Sulperazone	1
Vancomycin	1

Drug sensitivity testing was performed using the Kirby-Bauer (K-B) method. Fungal sensitivity testing was performed in accordance with ROSCO (Denmark).

GDM, gestational diabetes mellitus; GH, gestational hypertension; IVH, intraventricular haemorrhage; NEC, necrotising enterocolitis; PDA, patent ductus arteriosus; PICC, peripherally inserted central catheter; PROM, premature rupture of membranes; RDS, respiratory distress syndrome.

Table 2 Clinical characteristics of the infants

Clinical characteristics	Mean (SD) or n
Age at onset, days	15.85 (11.89)
Fever	2
Poor response	9
SaO ₂ instability	11
Apnoea	7
Jaundice	5
Abdominal distension	4
Poor peripheral perfusion	3

suggesting that a negative G test result does not mean the absence of CUC.

Our study reported clinical characteristics, treatment and prognosis of CUC in 13 infants. The infection was controlled successfully in all cases after intravenous administration of fluconazole. It is noteworthy that, in the three infants infected with CUC reported by Lukić-Grić *et al.*,⁷ one responded well to amphotericin B and the other two failed to respond to fluconazole and were later cured after replacement with amphotericin B and caspofungin, respectively. It was suggested that fluconazole could be used as the initial choice and, if it does not work effectively, it should be replaced by amphotericin B or echinocandins.

Contributors ZF conceived and designed the study. QL and LZ integrated and analysed data. QL and LZ drafted the original manuscript. SZ collected the clinical data. ZF edited the manuscript. All authors had full access to and verified the data. All the authors had final responsibility for the decision to submit the manuscript.

Funding This study was supported by National Key Research and Development Project (2021YFC2701700, 2021YFC2701701, 2021YFC2701702).

Competing interests None declared.

Patient and public involvement Patients and/or the public were not involved in the design, conduct, reporting or dissemination plans of this research.

Patient consent for publication Not applicable.

Provenance and peer review Not commissioned; externally peer reviewed.

Supplemental material This content has been supplied by the author(s). It has not been vetted by BMJ Publishing Group Limited (BMJ) and may not have been peer-reviewed. Any opinions or recommendations discussed are solely those of the author(s) and are not endorsed by BMJ. BMJ disclaims all liability and responsibility arising from any reliance placed on the content. Where the content includes any translated material, BMJ does not warrant the accuracy and reliability of the translations (including but not limited to local regulations, clinical guidelines, terminology, drug names and drug dosages), and is not responsible for any error and/or omissions arising from translation and adaptation or otherwise.

Open access This is an open access article distributed in accordance with the Creative Commons Attribution Non Commercial (CC BY-NC 4.0) license, which permits others to distribute, remix, adapt, build upon this work non-commercially, and license their derivative works on different terms, provided the original work is properly cited, appropriate credit is given, any changes made indicated, and the use is non-commercial. See: <http://creativecommons.org/licenses/by-nc/4.0/>.

ORCID iD

Zhichun Feng <http://orcid.org/0000-0002-9622-4062>

REFERENCES

- 1 Kaufman D, Fairchild KD. Clinical microbiology of bacterial and fungal sepsis in very-low-birth-weight infants. *Clin Microbiol Rev* 2004;17:638–80.
- 2 Ramasethu J. Prevention and treatment of neonatal nosocomial infections. *Matern Health Neonatol Perinatol* 2017;3:5.
- 3 Kossoff EH, Buescher ES, Karlowicz MG. Candidemia in a neonatal intensive care unit: trends during fifteen years and clinical features of 111 cases. *Pediatr Infect Dis J* 1998;17:504–8.
- 4 Gaisne R, Jeddi F, Morio F, *et al.* Candida utilis fungaemia following endoscopic intervention on ureteral stent in a kidney transplant recipient: case report and a review of the literature. *Mycoses* 2018;61:594–9.
- 5 Shivadasan J, Raksha K, Urs PS. Candida utilis causing neonatal candidemia – a case report and literature review. *Apollo Medicine* 2016;13:55–8.
- 6 McCarty TP, White CM, Pappas PG. Candidemia and invasive candidiasis. *Infect Dis Clin North Am* 2021;35:389–413.
- 7 Lukić-Grlić A, Mlinarić-Missoni E, Škarić I, *et al.* Candida utilis candidaemia in neonatal patients. *J Med Microbiol* 2011;60:838–41.